







# Comparative Assessment of E-cadherin's Expression between the Metastatic and Non-metastatic Oral Squamous Cell Carcinoma: An Immunohistochemical Study

Sufia Khan<sup>1</sup>, Veda Hegde<sup>2</sup>, Deepti Shrivastava<sup>3</sup>, Mohammed Azamulla<sup>4</sup>, Mohammad Khursheed Alam<sup>3,5,6</sup>, Kumar Chandan Srivastava<sup>7,8</sup>

<sup>1</sup>Department of Oral Pathology and Microbiology, Awadh Dental College & Hospital, Jamshedpur, Jharkhand, India.

<sup>2</sup>Department of Oral Pathology, SDM College of Dental Sciences & Hospital Sattur, Shri Dharmasthala Manjunatheswara University, Dharwad, India.

<sup>3</sup>Department of Preventive Dentistry, College of Dentistry, Jouf University, Sakaka, Saudi Arabia.

<sup>4</sup>Department of Periodontology and Implantology, Awadh Dental College & Hospital, Jamshedpur, Jharkhand, India.

<sup>5</sup>Department of Dental Research Cell, Saveetha Dental College and Hospitals, Saveetha Institute of Medical and Technical Sciences, Chennai, India

<sup>6</sup>Department of Public Health, Faculty of Allied Health Sciences, Daffodil International University, Dhaka, Bangladesh.

<sup>7</sup>Department of Oral and Maxillofacial Surgery & Diagnostic Sciences, College of Dentistry, Jouf University, Sakaka, Saudi Arabia.

<sup>8</sup>Department of Oral Medicine and Radiology, Saveetha Dental College, Saveetha Institute of Medical and Technical Sciences, Saveetha University, Chennai, India.

**Correspondence:** Kumar Chandan Srivastava, Department of Oral Maxillofacial Surgery & Diagnostic Sciences, College of Dentistry, Jouf University, Sakaka, Saudi Arabia. **E-mail:** [drkcs.omr@gmail.com](mailto:drkcs.omr@gmail.com)

**Academic Editor:** Wilton Wilney Nascimento Padilha

**Received:** 05 May 2022 / **Review:** 22 August 2022 / **Accepted:** 21 March 2023

**How to cite:** Khan S, Hegde V, Shrivastava D, Azamulla M, Alam MK, Srivastava KC. Comparative assessment of E-cadherin expression between the metastatic and non-metastatic oral squamous cell carcinoma: an immunohistochemical study. *Pesqui Bras Odontopediatria Clín Integr.* 2023; 23:e220077. <https://doi.org/10.1590/pboci.2023.077>

## ABSTRACT

**Objective:** To identify the clinicopathological correlation of E-cadherin expression in metastatic and non-metastatic oral squamous cell carcinoma (OSCC). **Material and Methods:** A total of 90 paraffin-embedded tissue sections of OSCC were retrieved from the registry. The total selected samples were 45 cases each from the primary lesions of metastatic and non-metastatic OSCC. One section was subjected to routine Hematoxylin and eosin stain and another to immunohistochemical analysis for E-cadherin expression.

**Results:** A non-significant ( $p>0.05$ ) increased expression is seen in the non-metastatic group compared to the metastatic group, with predominantly membrane as the staining site in either group. However, the expression of E-cadherin did not reveal any statistically significant association with independent variables such as age, gender, and adverse habits of the patients ( $p>0.05$ ). On the other hand, with respect to the histological differentiation of OSCC, a significant association ( $p<0.001$ ) was observed with the well-differentiated type of metastatic OSCC. **Conclusion:** E-cadherin was useful to some extent in predicting regional metastasis. However, further studies using a panel of biomarkers with increased sample size may help us understand the process involved in metastasis.

**Keywords:** Cadherins; Cell Adhesion; Squamous Cell Carcinoma of Head and Neck; Neoplasm Metastasis.

## Introduction

Cell adhesion is one of the elementary mechanisms that carry out a decisive role in the proper functioning of a multicellular organism. This involves an array of cell adhesion molecules (CAMs) that carry out diverse tasks such as cell-to-cell and cell-to-matrix interplay, cell migration, cell kinetics, and a multitude of cell signaling mechanisms [1]. Additionally, they participate in the process of morphogenesis during the development and regeneration of the tissue [2,3]. The crucial role of CAMs can be attributed to the fact that CAMs are seen to be associated with a wide variety of pathological conditions such as inflammatory, infectious, malignancies, and autoimmune diseases [3,4].

The life cycle of tissue from development, maintenance, and repair demands a delicate balance between the three phenomena, namely cellular proliferation, adhesion, and motility [5]. The occurrence of tumour initiation and progression is marked by the anomalous expression of genes responsible for cell proliferation and survival and by genes controlling cell adhesion and motility [6-9].

Based on the structure, four major families of CAMs, including Integrins, Selectins, CAMs of the immunoglobulin gene (IgG-like) superfamily, and cadherins, have been identified [10]. Among the four, Cadherin is identified as a transmembrane calcium ( $\text{Ca}^{2+}$ ) dependent homophilic adhesion receptor. They are pivotal in multiple functions, such as setting up and sustaining intercellular connections, managing cell polarity, morphogenesis, cell recognition, and cell sorting. E-cadherin is principally recognized as a tumour suppressor gene [11-13]. Among the family of cadherins, E-cadherin is one of the critical molecules known to facilitate cell-to-cell adhesion on the adherence junctions located at the epithelial surface [13]. As a member of a vast family of genes engaged in coding for CAMs, the cadherin glycoproteins are expressed by a large variety of tissues, arbitrating adhesion via homotypic binding. During tissue formation stages such as gastrulation, neurulation, and organogenesis, classical cadherins play a key role [14,15].

Apart from its contribution to the physiological homeostasis of normal cells, this gene also plays a significant role in malignant transformation, especially during the stages of tumour development and progression, by facilitating invasion and metastasis [16]. The latter is considered one of the hallmarks in the pathogenesis of oral carcinoma [17,18]. In a recently conducted global survey on the incidence and mortality rate of cancer- GLOBOCAN 2020, the data shows the increased global burden of cancer. The survey studied the magnitude and geographical distribution of major cancer types. As per the survey result, it was estimated that 19.3 million new cancer cases and almost 10.0 million cancer deaths have occurred globally in 2020, and a rise of 47% is expected by 2040, primarily due to increasing risk factors associated with globalization and a growing economy. According to the survey, Asia accounted for a higher fatality rate of 58.3% when both genders were considered [19]. The correlation between the reduced or absence of E-cadherin expression and invasive properties may not be a general phenomenon since invasiveness of cells and de-differentiation of carcinomas can occur even during the existence of E-cadherin [20,21]. The quelling of E-cadherin expression is considered one of the established elementary molecular phenomena accountable for the dysfunction in cell-cell adhesion. Thus, the present study aimed to retrospectively evaluate E-cadherin's immunohistochemical (IHC) expression in the tissue samples of patients with metastatic and non-metastatic forms of oral squamous cell carcinoma.

## Material and Methods

### Sample Characteristics

A retrospective cross-sectional study was designed for two years, ranging from 2020-2021, after the due approval from the ethics committee.

Forty-five paraffin-embedded tissue blocks of histopathologically confirmed primary lesions of metastatic (Group I) and non-metastatic (Group II) OSCC were gathered from the department's registry, making a total sample of ninety. The sample size was calculated with G\*Power software with a confidence interval of 95% and an effect size of 0.5. The blocks' inaccuracy regarding inadequate connective tissue depth or folded or necrotic tissues was excluded. The study did not include histopathological samples of the patients with a history of recurrent OSCC or blocks with incomplete clinical data.

#### Immunohistochemical (IHC) Analysis

According to the instructions of the manufacturer (Pathnsitu, Gene Pulse Scientific Bangalore), the IHC method was carried out. The primary antibody was an E-cadherin rabbit monoclonal antibody (Clone EPR4120, IgG immunoglobulin). The antibody was used from PathnSitu Biotechnologies (Gene Pulse Scientific, Bangalore, India). A supersensitive polymer – HRP detection system, a biotin-free detection system supplied by PathnSitu Biotechnologies (Gene Pulse Scientific, Bangalore, India), was the visualization kit utilized, which carried the chromogen –Diaminobenzidine (DAB). Antigen heat retrieval was done using a pressure cooker (Tris-EDTA buffer; pH 9.0). All the reagents stored in the refrigerator at 4–8°C were brought to room temperature prior to staining. Positive controls in the current study belong to the colon with known antigenic reactivity to E-cadherin.

#### Interpretation of Staining

The appearance of brown-coloured end product at the target antigen site was contemplated as positive immune reactivity, and the same was appreciated in the positive control sections.

- Membranous staining for E-cadherin was considered positive.
- Membranous and cytoplasmic stains for E-cadherin were considered positive.
- Cytoplasmic staining alone and unstained cells for E-cadherin were considered negative for the expression.

The sections of the primary lesions were scanned under low power magnification (x10) at the invasive front in both metastatic and non-metastatic OSCC to determine the areas to be counted. Folded sections and areas not identifiable for counting were noted and not considered for counting in higher magnification (x40).

The counting was done with a binocular light microscope under (x40). The immune reactivity was evaluated semi-quantitatively based on the distribution and staining intensity. The total number of tumour cells counted at the invasive tumour front (ITF) in each slide was 1000. The numbers of positive and negatively stained cells were noted based on the criterion mentioned above.

The percentage of positive tumour cells is obtained by the simple formula as shown:

Total number of positive tumour cells: Membrane (M):  $M \% = M / 1000 \times 100$  **or**

Mixed i.e. membrane and cytoplasm (M + C):  $(M+C) / 1000 \times 100$

Total number of tumour-positive cells were categorized based on Intensity reactive score (IRS) as follows: 1) 0 % = 0; 2) 1-30% = 1; 3) 30-60% =2; 4) >60% = 3 [20].

#### Data Analysis

The data was analysed employing IBM SPSS Statistics 20.0 software (IBM Corp., Armonk, NY, USA). An inferential statistical test was performed using the Chi-square test. A p-value of <0.05 was considered to indicate statistical significance.

## Results

### Sample Characteristics

The patients in either group were predominantly males (Group I – 34; Group II – 36), and the majority were in the age group of >60 Years (Group I – 17; Group II – 15). The majority (n=39) of group I patients presented with primary lesions in the buccal mucosa followed by a lateral border of the tongue. Unlike group I, there were several sites involved in group II apart from buccal mucosa, including the floor of the mouth, palate, mandibular alveolus, gingivobuccal sulcus (GBS), retromolar trigone region and commissure of the mouth. The use of a smokeless form of tobacco was prevalent in both groups (Group I – 32; Group II – 31), followed by tobacco smoke form, mixed habits (smokeless tobacco & cigarette smoking), and a tiny group of patients without any known adverse habits (Table 1).

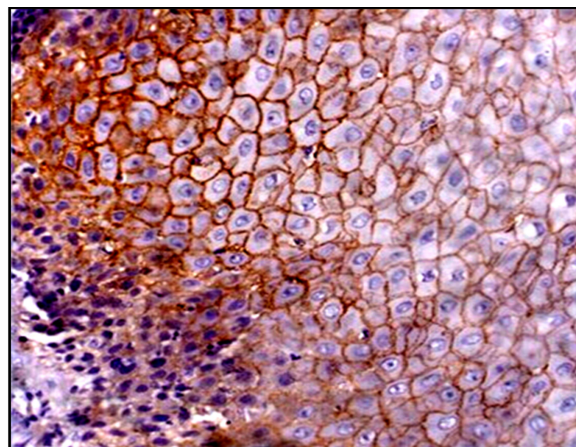
**Table 1. Sample characteristics.**

Variables	Categories	Groups	
		G I (Metastatic) N (%)	G II (Non-Metastatic) N (%)
Age	<39 Years	9 (20.0)	8 (17.7)
	40-49 Years	8 (17.7)	10 (22.2)
	50-59yrs	11 (24.4)	12 (26.6)
	> 60 Years	17 (37.7)	15 (33.3)
Mean ± SD (Min.; Max.)		47.73±12.39 (29; 78)	51±12.38 (25; 75)
Gender	Male	34 (75.5)	36 (80.0)
	Female	11 (24.4)	9 (20.0)
Adverse Habit	Smokeless	32 (71.1)	31 (68.9)
	Smoking	11 (24.4)	10 (22.2)
	Combination	2 (4.4)	4 (8.9)
Site of Lesion	Buccal Mucosa	39 (86.7)	26 (57.8)
	Lateral border of the tongue	3 (6.7)	3 (6.7)
	Other sites	3 (6.7)	16 (35.6)
Histopathological Grades	Well Differentiated	30 (66.6)	32 (71.1)
	Moderately Differentiated	9 (20.0)	8 (17.7)
	Poorly Differentiated	6 (13.3)	5 (11.1)

SD: Standard Deviation; Min.: Minimum; Max.: Maximum.

### Slide Observations of Immunohistochemistry

This expression of E-cadherin was observed depending on the localization pattern in membranous, cytoplasmic, mixed (membranous and cytoplasmic), and without staining (Figures 1 to 4).



**Figure 1. Dysplastic oral epithelium in metastatic OSCC showing predominantly intense membranous staining (Immunostaining, DAB chromogen-E-cadherin antibody, Inset-x40).**

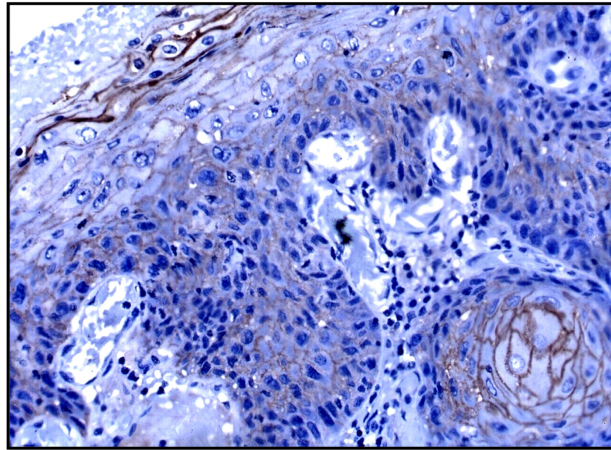


Figure 2. Dysplastic oral epithelium in non-metastatic OSCC showing predominantly intense membranous in the centre and decrease staining at the periphery of the island (Immunostaining, DAB chromogen-E-cadherin antibody, original magnification, Inset -x40).

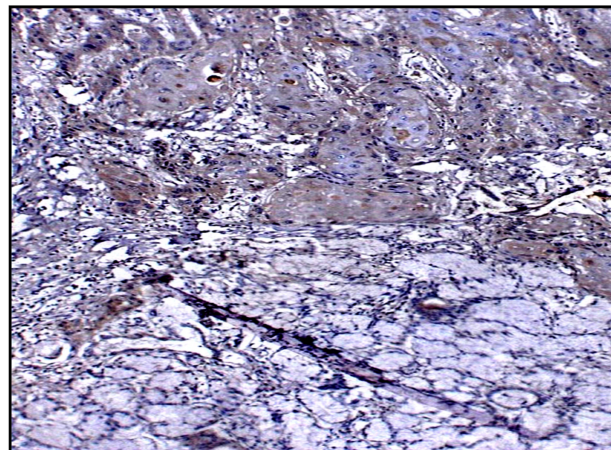


Figure 3. Tumour islands in close proximity (yellow arrowhead) and invading (yellow arrow) mucous acini in metastatic OSCC (Immunostaining, DAB chromogen-E-cadherin antibody, original magnification; Inset -x10).

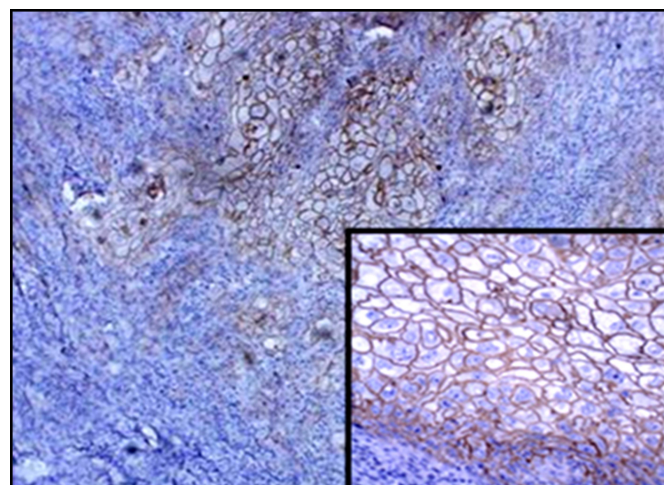


Figure 4. Tumour islands in metastatic OSCC shows characteristic intense membranous stain in the tumour islands (Immunostaining, DAB chromogen-E-cadherin antibody, original magnification x10; Inset- x40).

A non-significant, predominantly membranous staining was observed in both groups. A statistically non-significant ( $p > 0.05$ ) increased expression of E-cadherin in terms of intensity was observed in non-metastatic OSCC (Group II) as compared to metastatic OSCC (Table 2).

**Table 2. Comparative evaluation of pattern and intensity of E-cadherin staining among the study groups.**

Variables	Categories	Groups		p-value
		G I N (%)	G II N (%)	
Site of Staining <sup>‡</sup>	Predominantly Membranous	38 (84.4)	39 (86.7)	0.84
	Predominantly Cytoplasmic	3 (6.6)	5 (11.1)	
	No Staining	4 (8.8)	1 (2.2)	
Staining Index <sup>†</sup> (IRS Score)	No Stain	4 (8.8)	1 (2.2)	0.51
	1-30	19 (42.2)	15 (33.3)	
	31-60	20 (44.4)	23 (51.1)	
	> 61	2 (4.4)	6 (13.3)	

<sup>‡</sup>Results expressed in number (%); <sup>†</sup>Expressed as count (% within Site of Lesion); IRS: Intensity Reactive Score.

Independent variables such as age, gender, lesion site, and nature of adverse habits did not show any significant association ( $p > 0.05$ ) with site or intensity of staining in either group. However, a significant positive association ( $p < 0.001$ ) was found between the intensity of E-cadherin expression and histopathological grades of differentiation in metastatic OSCC (Table 3).

**Table 3. Inferential analysis of immunochemistry parameters with independent variables.**

Groups	Immunochemistry Parameter	Independent Variables				
		Age	Gender	Adverse Habit	Site of Lesion	Histopathological Grading
G I	Site of Staining	0.66	0.82	0.79	0.69	0.66
	Staining Index	0.65	0.95	0.60	0.86	<0.001
G II	Site of Staining	0.32	0.05	0.89	0.64	0.58
	Staining Index	0.7	0.09	0.67	0.41	0.53

## Discussion

Cellular adhesion plays an important role in normal physiology and various pathological conditions. Cell-cell and cell-matrix contacts are necessary for proper epithelial tissue and function. They play a vital role in signal transduction for regulating cell adhesion, motility, growth, apoptosis, site-specific gene regulation, wound healing, and inflammation [1,3]. To achieve these intercellular adhesions, cells possess various cell junctions. These include anchoring junctions/adhesive junctions, occluding junctions/tight junctions, and nexus junctions/ gap junctions [22,23]. Interaction between the cytoskeleton and the adherens junction is considered the most common type of intercellular adhesion. Cell adhesion molecules such as Cadherin, Integrins, Selectins, and Immunoglobulin superfamily determine the epithelial phenotype through homophilic cell adhesions and polarity [16].

Cadherins are a 120 kD glycoprotein calcium-dependent family of cell adhesion molecules that mediates homophilic cell interactions between epithelial cells. The adhesive interactions are mediated by cadherin extracellular domains and are coupled to the interior of cells by a series of cytoskeletal linking proteins [10]. The cytoplasmic domain of the cadherins interacts with beta-catenin, members of the Armadillo gene family, and constitutes the peripheral membrane proteins. It is considered a primary mediator between the epithelial cells, which play a crucial role in normal tissue morphogenesis in addition to cell segregation as well as tissue differentiation [4]. Beta-catenin is an oncogenic transcription factor. The probable mechanisms linked to the

loss of membranous expression of E-cadherin/-catenin are primarily related to the development of the epithelial-mesenchymal transition phenomenon that induces an increased invasion of tumour cells or lymph node metastasis [6].

Normal and hyperplastic epithelium showed intense pericellular staining in the basal, suprabasal, and prickle cell layers. The keratinizing superficial layers are negative [24]. Although the mechanisms regulating E-cadherin expression in the upper layers of the epithelium are not fully understood, it is assumed that the loss of expression may play a role in the normal desquamation of the epithelium. Tyrosine phosphorylation can initiate the disassembly of the complex during normal cell migration. Phosphorylation of the E-cadherin-catenin complex, principally of beta-catenin, promotes delocalization of membrane-bound E-cadherin from the adherens junctions [25].

In the present study, the expression of E-cadherin in the primary lesions and various clinical parameters like gender, age, location of the primary tumour, habits, histological grades, and association with and without metastasis were correlated and analyzed between the two study groups.

The expression of E-cadherin was studied concerning the location of the lesion in their study. However, there was no statistically significant association between the immunostaining with E-cadherin and the lesion site. In his research, Tanaka et al. [26] found that the predominant site of occurrence of OSCC was the tongue, with no association with the expression of E-cadherin expression with the location of the lesion, as seen in our case.

There are conflicting results in studies that correlate the expression of E-cadherin and the grade of histologic differentiation. In the present study, most cases were well-differentiated squamous cell carcinoma on histological examination in both metastatic and non-metastatic OSCC. With respect to histological differentiation and E-cadherin expression, only well-differentiated OSCC and E-cadherin expression exhibited a statistical correlation between the two study groups. However, the expression of E-cadherin in the well-differentiated type of metastatic OSCC was more than that noted in the well-differentiated type of non-metastatic OSCC.

In their study, Sterlacci et al. [27] found that well-differentiated squamous cell carcinoma showed greater E-cadherin expression than moderately differentiated OSCC, with poorly differentiated OSCC showing the slightest expression. A similar observation was also noted by, Bagutti et al. [4] and Kaur et al. [12], who found that the least differentiated tumors showed a reduced expression of E-cadherin than the differentiated tumours, which was statistically significant. They also noted that E-cadherin immunoreactivity correlated with the loss of cell differentiation inversely. Furthermore, E-cadherin expression was negative in most metastatic lymph nodes [4,12].

In a similar study by Balasundaram et al. [5], who analyzed E-cadherin expression in OSCC with clinicopathological variables (age, sex, site, size of tumour, histological differentiation, and stage), did not consider E-cadherin as a prognostic indicator. They postulated that several factors related to methodology may account for the inconsistency in the results. The techniques of immunostaining evaluation and the concept of under-expression do not match, compromising accurate data comparison [5].

Hung et al. analyzed the expression of E-cadherin at the primary site and lymph node tissue of OSCC. It was noted that expression of E-cadherin was more at the primary site of OSCC due to the loss of E-cadherin compared to nodal tissue [25]. On the contrary, according to Kowalski et al. [13], E-cadherin expression was higher in the nodal tissues of OSCC compared to the primary site. A possible reason could be the re-expression of E-cadherin at the nodal tissue. Similar findings were noted by Myong [24], who has reported a statistically significant inverse correlation between E-cadherin immunoexpression in OSCC.

Research based on the meta-analytical study [28] showed that the overall survival (OS) state as well as disease-free survival (DFS) rate in head & neck SCC, is proportionate with each other, i.e., with decreased expression of E-cadherin there is a simultaneous decrease in OS as well DFS both.

Similar speculation wherein the prognosis of OSCC was analysed, and it was further concluded that there was a strong significant association between the E-Cadherin expression with pooled hazard ratio and OS [29].







Although the current literature has a sufficient number of studies stating the role of E-cadherin in metastasis, the underlying mechanism through which the metastasis occurs is still under debate, and the results are consistent with the clinical parameters and with few previous studies.

Hence, further studies need to be undertaken to further investigate on a larger scale using multiple panels of markers or better methods, which may provide more insights to clarify this interesting field of study better and might aid in an understanding of the molecular nature of tumour spread and helps in useful in predicting the treatment protocol for the betterment of the patient's survival.

## Conclusion

Through this study, we have attempted to correlate the expression of E-cadherin in primary metastatic and non-metastatic oral squamous cell carcinoma and also with clinicopathological parameters such as gender, age, site, habit, and histopathological grades of oral squamous cell carcinoma. No statistically significant difference was analysed concerning the above-mentioned clinical parameters except in histopathological grades of oral squamous cell carcinoma, where a statistically significant correlation exists with respect to well-differentiated oral squamous cell carcinoma in metastatic oral squamous cell carcinoma. E-cadherin was useful to some extent in predicting regional metastasis. However, further studies using a panel of biomarkers with increased sample size may help us understand the process involved in metastasis.

## Authors' Contributions

SK	 <a href="https://orcid.org/0000-0001-9631-3842">https://orcid.org/0000-0001-9631-3842</a>	Conceptualization, Methodology, Resources, Writing - Original Draft and Writing - Review and Editing.
VH	 <a href="https://orcid.org/0000-0001-9136-2709">https://orcid.org/0000-0001-9136-2709</a>	Conceptualization, Methodology, Resources, Writing - Original Draft and Writing - Review and Editing.
DS	 <a href="https://orcid.org/0000-0002-1073-9920">https://orcid.org/0000-0002-1073-9920</a>	Conceptualization, Resources, Writing - Original Draft and Writing - Review and Editing.
MA	 <a href="https://orcid.org/0000-0003-0628-7762">https://orcid.org/0000-0003-0628-7762</a>	Methodology, Software, and Writing - Review and Editing.
MKA	 <a href="https://orcid.org/0000-0001-7131-1752">https://orcid.org/0000-0001-7131-1752</a>	Conceptualization, Writing - Original Draft, and Writing - Review and Editing.
KCS	 <a href="https://orcid.org/0000-0002-5969-6810">https://orcid.org/0000-0002-5969-6810</a>	Conceptualization, Methodology, Writing - Original Draft and Writing - Review and Editing.
All authors declare that they contributed to a critical review of intellectual content and approval of the final version to be published.		

## Financial Support

None.

## Conflict of Interest

The authors declare no conflicts of interest.

## Data Availability

The data used to support the findings of this study can be made available upon request to the corresponding author.

## Acknowledgments

The authors would like to thank the Department of Oral and Maxillofacial Pathology SDM College of Dental Sciences Dharwad, India, for the support in the collection of data.



## References

- [1] Maître JL, Heisenberg CP. Three functions of cadherins in cell adhesion. *Curr Biol* 2013; 23(14):R626-33. <https://doi.org/10.1016/j.cub.2013.06.019>
- [2] Harjunpää H, Lloret Asens M, Guenther C, Fagerholm SC. Cell adhesion molecules and their roles and regulation in the immune and tumor microenvironment. *Front Immunol* 2019; 10:1078. <https://doi.org/10.3389/fimmu.2019.01078>
- [3] Ren G, Roberts AI, Shi Y. Adhesion molecules: key players in Mesenchymal stem cell-mediated immunosuppression. *Cell Adh Migr* 2011; 5(1):20-2. <https://doi.org/10.4161/cam.5.1.13491>
- [4] Bagutti C, Speight PM, Watt FM. Comparison of integrin, cadherin, and catenin expression in squamous cell carcinomas of the oral cavity. *J Pathol* 1998; 186(1):8-16.
- [5] Balasundaram P, Singh MK, Dinda AK, Thakar A, Yadav R. Study of  $\beta$ -catenin, E-cadherin and vimentin in oral squamous cell carcinoma with and without lymph node metastases. *Diagn Pathol* 2014; 9:145. <https://doi.org/10.1186/1746-1596-9-145>
- [6] Ramos-García P, González-Moles MÁ. Prognostic and clinicopathological significance of the aberrant expression of  $\beta$ -catenin in oral squamous cell carcinoma: a systematic review and meta-analysis. *Cancers* 2022; 14(3):479. <https://doi.org/10.3390/cancers14030479>
- [7] Behrens J, Vakaet L, Friis R, Winterhager E, Van Roy F, Mareel MM, et al. Loss of epithelial differentiation and gain of invasiveness correlates with tyrosine phosphorylation of the E-cadherin/beta-catenin complex in cells transformed with a temperature-sensitive v-SRC gene. *J Cell Biol* 1993; 120(3):757-66. <https://doi.org/10.1083/jcb.120.3.757>
- [8] Choi W, Porten S, Kim S, Willis D, Plimack ER, Hoffman-Censits J, et al. Identification of distinct basal and luminal subtypes of muscle-invasive bladder cancer with different sensitivities to frontline chemotherapy. *Cancer Cell* 2014; 25(2):152-65. <https://doi.org/10.1016/j.ccr.2014.01.009>
- [9] Doğan A, Wang ZD, Spencer J. E-cadherin expression in intestinal epithelium. *J Clin Pathol* 1995; 48(2):143-6. <https://doi.org/10.1136/jcp.48.2.143>
- [10] Kim HN, Ruan Y, Ogana H, Kim YM. Cadherins, selectins, and integrins in CAM-DR in leukemia. *Front Oncol* 2020; 10:592733. <https://doi.org/10.3389/fonc.2020.592733>
- [11] Field JK. Oncogenes and tumour suppressor genes in squamous cell carcinoma of the head and neck. *Eur J Cancer B Oral Oncol* 1992; 28B(1):67-76. [https://doi.org/10.1016/0964-1955\(92\)90016-t](https://doi.org/10.1016/0964-1955(92)90016-t)
- [12] Kaur G, Carnelio S, Rao N, Rao L. Expression of E-cadherin in primary oral squamous cell carcinoma and metastatic lymph nodes: An immunohistochemical study. *Indian J Dent Res* 2009; 20(1):71-6. <https://doi.org/10.4103/0970-9290.49075>
- [13] Kowalski PJ, Rubin MA, Kleer CG. E-cadherin expression in primary carcinomas of the breast and its distant metastases. *Breast Cancer Res* 2003; 5(6):R217-22. <https://doi.org/10.1186/bcr65>
- [14] Gall TM, Frampton AE. Gene of the month: E-cadherin (CDH1). *J Clin Pathol* 2013; 66(11):928-32. <https://doi.org/10.1136/jclinpath-2013-201768>
- [15] Gottardi CJ, Gumbiner BM. Adhesion signaling: how  $\beta$ -catenin interacts with its partners. *Current boil* 2001; 11(19):R792-4. [https://doi.org/10.1016/s0960-9822\(01\)00473-0](https://doi.org/10.1016/s0960-9822(01)00473-0)
- [16] Pećina-Šlaus N. Tumor suppressor gene E-cadherin and its role in normal and malignant cells. *Cancer Cell Int* 2003; 3(1):1-7. <https://doi.org/10.1186/1475-2867-3-17>
- [17] Srivastava KC. Comparative evaluation of saliva's oxidant-antioxidant status in patients with different clinicopathological types of oral leukoplakia. *J Int Soc Prev Community Dent* 2019; 9(4):396-402. [https://doi.org/10.4103/jispcd.JISPCD\\_179\\_19](https://doi.org/10.4103/jispcd.JISPCD_179_19)
- [18] Srivastava KC, Austin RD, Shrivastava D. Evaluation of oxidant-antioxidant status in tissue samples in oral cancer: a case control study. *Dent Res J* 2016; 13(2):181-7. <https://doi.org/10.4103/1735-3327.178210>
- [19] Sung H, Ferlay J, Siegel RL, Laversanne M, Soerjomataram I, Jemal A, et al. Global cancer statistics 2020: GLOBOCAN estimates of incidence and mortality worldwide for 36 cancers in 185 countries. *CA Cancer J Clin* 2021; 71(3):209-49. <https://doi.org/10.3322/caac.21660>
- [20] Hedrick L, Cho KR, Vogelstein B. Cell adhesion molecules as tumour suppressors. *Trends Cell Biol* 1993; 3(2):36-9. [https://doi.org/10.1016/0962-8924\(93\)90148-t](https://doi.org/10.1016/0962-8924(93)90148-t)
- [21] Huber GF, Zullig L, Soltermann A, Roessle M, Graf N, Haerle SK, et al. Down-regulation of E-cadherin (ECAD) - a predictor for occult metastatic disease in sentinel node biopsy of early squamous cell carcinomas of the oral cavity and oropharynx. *BMC Cancer* 2011; 11(217):211-8. <https://doi.org/10.1186/1471-2407-11-217>
- [22] Downer CS, Speight PM. E-cadherin expression in normal, hyperplastic and malignant oral epithelium. *Eur J Cancer B Oral Oncol* 1993; 29B(4):303-5. [https://doi.org/10.1016/0964-1955\(93\)90053-h](https://doi.org/10.1016/0964-1955(93)90053-h)
- [23] Freemont AJ. Demystified adhesion molecules. *Mol Pathol* 1998; 51(4):175-84. <https://doi.org/10.1136/mp.51.4.175>
- [24] Myong NH. Loss of E-cadherin and acquisition of vimentin in epithelial-mesenchymal transition are noble indicators of uterine cervix cancer progression. *Korean J Pathol* 2012; 46(4):341-8. <https://doi.org/10.4132/KoreanJPathol.2012.46.4.341>
- [25] Hung KF, Chang CS, Liu CJ, Lui MT, Cheng CY, Kao SY. Differential expression of E-cadherin in metastatic lesions comparing to primary oral squamous cell carcinoma. *J Oral Pathol Med* 2006; 35:589-94. <https://doi.org/10.1111/j.1600-0714.2006.00474.x>

- [26] Tanaka N, Odajima T, Ogi K, Ikeda T, Satoh M. Expression of E-cadherin, alpha-catenin, and beta-catenin in the process of lymph node metastasis in oral squamous cell carcinoma. *Br J Cancer* 2003; 89:557-63. <https://doi.org/10.1038/sj.bjc.6601124>
- [27] Sterlacci W, Fiegl M, Hilbe W, Jamnig H, Oberaigner W, Schmid T, et al. Deregulation of p27 and cyclin D1/D3 control over mitosis is associated with unfavorable prognosis in non-small cell lung cancer, as determined in 405 operated patients. *J Thorac Oncol* 2010; 5(9):1325-36. <https://doi.org/10.1097/JTO.0b013e3181e77efc>
- [28] Yazdani J, Ghavimi MA, Jabbari Hagh E, Ahmadpour F. The role of E-cadherin as a prognostic biomarker in head and neck squamous carcinoma: a systematic review and meta-analysis. *Mol Diagn Ther* 2018; 22(5):523-35. <https://doi.org/10.1007/s40291-018-0351-y>
- [29] Luo SL, Xie YG, Li Z, Ma JH, Xu X. E-cadherin expression and prognosis of oral cancer: a meta-analysis. *Tumour Biol* 2014; 35(6):5533-7. <https://doi.org/10.1007/s13277-014-1728-0>